



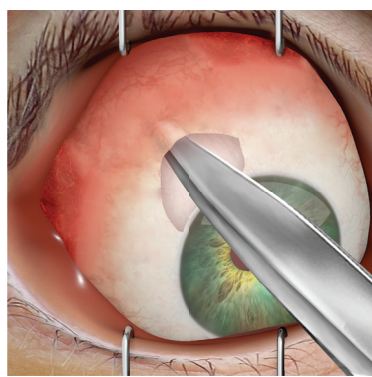
The Ahmed® ClearPath™ Surgical Procedure

Step 1



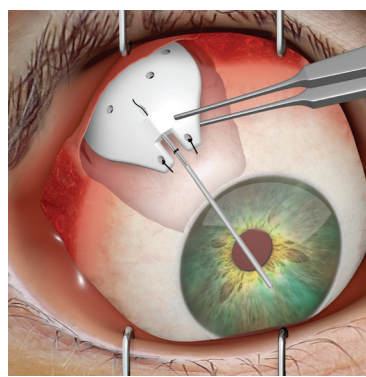
The tube must be ligated near the tube-plate junction preferably with a **7-0 vicryl dissolvable suture** to occlude the tube. One technique to occlude the tube involves the placement of a releasable ripcord in the tube lumen at the time of the initial surgery. A 7-0 vicryl dissolvable suture is placed around the tube (and consequently around the ripcord) and tightened to prevent any flow through the tube and around the ripcord. A 4-inch 4-0 polypropylene ripcord (preloaded in the tube lumen) is provided with the implant.

Step 2



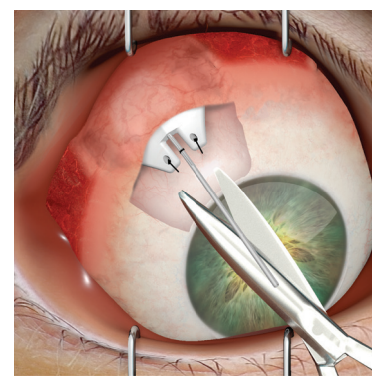
A conjunctival peritomy incision is made. A pocket is formed superiorly, avoiding the superior rectus and oblique muscles, with blunt dissection of Tenon's capsule from the episclera.

Step 3



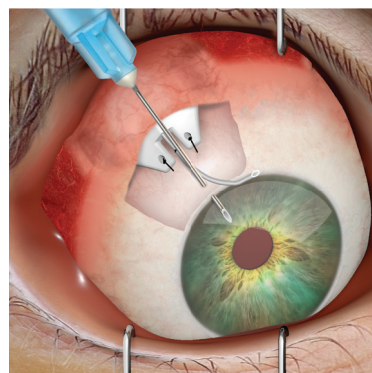
The implant is placed away from the limbus under the conjunctiva and tenon's capsule between the rectus muscles (the endplate of the model 350 is wider than the model 250 endplate and has portions that fit under adjacent rectus muscles) and sutured to the episclera. The leading edge of the endplate should be ~ 8-10 mm from the limbus resulting in the suture arms being 6-8 mm from the limbus when implanted in the superior quadrants or 4-6 mm when implanted in the inferior quadrants.

Step 4



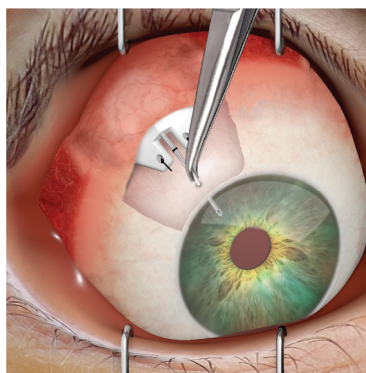
The drainage tube is trimmed to permit a **2-3 mm** insertion of the tube into the anterior chamber. The tube should be bevel cut to an anterior angle of 30° to facilitate insertion.

Step 5



The AC is entered at **1-2 mm** way from the limbus with a sharp **23-gauge** needle to create a needle track, parallel to the iris. In addition, a paracentesis should be performed to allow for quick AC reformation in case of a flattened anterior chamber.

Step 6



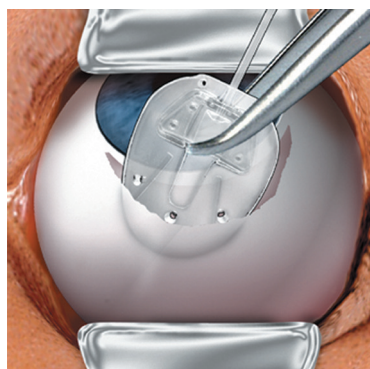
The drainage tube is inserted approximately **2-3 mm** into the anterior chamber through the previously created needle track.

Step 7

After surgery, the body's wound healing mechanism results in the formation of a fibrous capsule (bleb) composed of scar tissue around the implant, this scar tissue resists fluid outflow. In approximately 4-6 weeks the 7-0 vicryl suture dissolves. At that time, under a magnified view of a slit lamp biomicroscope or operating microscope the conjunctiva can be entered over the temporal side of the ripcord and the ripcord be removed using jeweler's forceps. Following the ripcord removal, the IOP should be checked and slit lamp and fundoscopic examination should be performed.

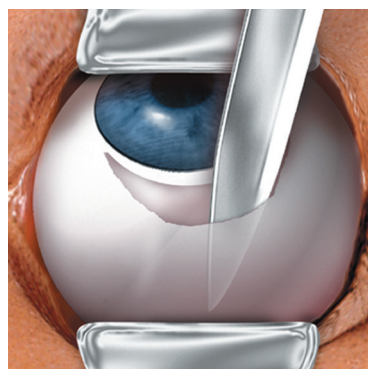
The Ahmed® Glaucoma Valve Surgical Procedure

Step 1



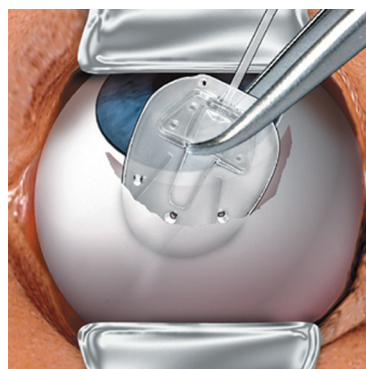
The implant should be examined and primed prior to implantation. Priming is accomplished by injecting 1cc balanced salt solution or sterile water through the drainage tube and valve, using a blunt **26 gauge cannula**.

Step 1



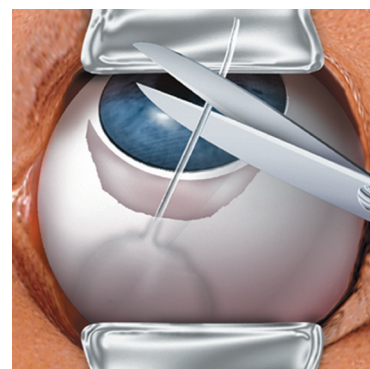
A fornix-based incision is made through the conjunctiva and Tenon's capsule. A pocket is formed at the superior quadrant between the medial or lateral rectus muscles by blunt dissection of Tenon's capsule from the episclera.

Step 3



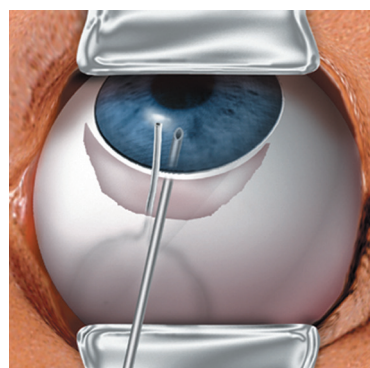
The valve body is inserted into the pocket between the rectus muscles and sutured to the episclera. The leading edge of the plate should be at least **8-10mm from the limbus**.

Step 4



The drainage tube is trimmed to permit a **2-3 mm** insertion of the tube into the anterior chamber (AC). The tube should be bevel cut to an anterior angle of 30° to facilitate insertion.

Step 5

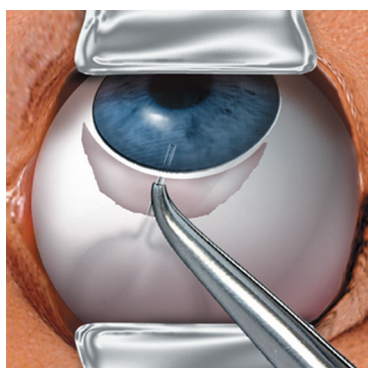


A paracentesis is performed, and the AC is entered at **1-2 mm** way from the limbus with a sharp 23 gauge needle to create a needle track, parallel to the iris.

Caution: Care must be taken to ensure that the drainage tube does not contact the iris or corneal endothelium after insertion.

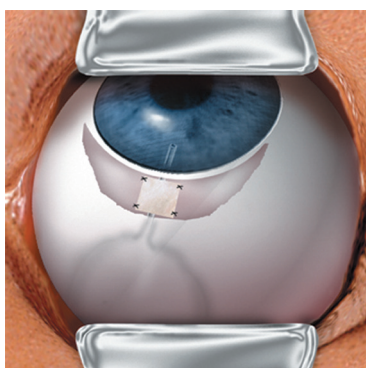
Note: Some surgeons prefer to enter the AC from at least 3mm away from the limbus.

Step 6



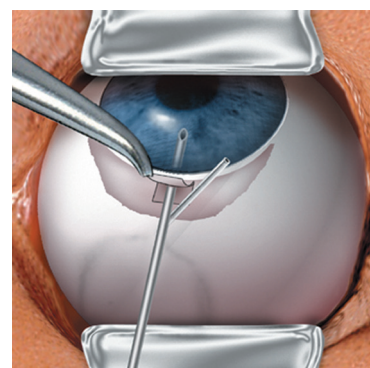
The drainage tube is inserted approximately **2-3 mm** into the AC through the needle track created in step 5.

Step 7



The exposed drainage tube is covered with a piece of preserved, donor sclera, pericardium, cornea, or other suitable patch graft material which is sutured into place and the conjunctiva is closed.

Note: As an alternative to Step 7, a **2/3 thickness limbal-based scleral flap** may be made. The tube is inserted into the AC through a 23 gauge needle puncture made under the flap. The flap is sutured closed.



The steps illustrated here are intended as a **guideline only**, and do not represent recommended treatment for any particular patient. The use of any specific surgical technique or maneuver is at the sole discretion of the surgeon. Surgeons should be familiar with the use of glaucoma drainage devices and post-operative care considerations before implanting any drainage device. Reference papers and surgical video tapes are available upon request.