

GONIOTOMY WITH A DUAL BLADE

Advice for surgeons interested in adopting this procedure.

BY MICHAEL G. MORGAN, MD



Surgically active ophthalmologists, especially those with large glaucoma practices, have long appreciated the need for advances in glaucoma surgery. Traditional approaches have done little to address the large population of patients who are burdened with glaucoma medications. The cost and burden of eye drops are well documented, and the preservatives in these products can cause long-term toxicity to the ocular surface. Additionally, glaucomatous progression is associated with diurnal variations in IOP caused by poor adherence to prescribed regimens.^{1,2} Any safe procedure designed to decrease dependence on patient-administered drops would be a welcome addition to the glaucoma treatment armamentarium.

Goniotomy, such as that performed with the Kahook Dual Blade (KDB; New World Medical), is a minimally invasive surgical option for glaucoma. The procedure does not violate the scleral wall and is not associated with a bleb. By removing a section of trabecular tissue, the KDB gives aqueous direct access to the collector channels and the distal outflow system. Although goniotomy performed with the KDB is similar to the procedure performed with the Trabectome (NeoMedix), the KDB does not require a capital outlay; the cost is limited to that of the blade. This results in a per-case cost that is significantly lower with the KDB compared with the Trabectome.

ADOPTION

Having experience in ab interno surgery eased my adoption of goniotomy. An ophthalmologist who has not performed angle surgery will first need to become comfortable using a gonioscope. As with other surgical techniques, operative use of the gonioscope is a learned skill that requires practice (Figure).

At the outset, I recommend performing intraoperative gonioscopy on cataract surgery patients without performing actual angle surgery. Prior to removing the viscoelastic and after inserting the IOL, the ophthalmologist rotates the patient's head, tilts the microscope, applies the gonioscope, and visualizes the angle. With repetition, the surgeon will

become confident in this maneuver. The tip of the viscoelastic cannula can be advanced through the corneal incision until it reaches the angle. This will allow the learning surgeon to become comfortable with the combination of using the gonioscope and working with an instrument in this previously unfamiliar space. After performing these steps for roughly five cases, I felt ready to proceed with actual surgery.

The position of the patient's head and maintenance of a clear view are vital in angle surgery. The degree to which the head is turned and the microscope tilted varies from patient to patient. Insufficient rotation of the head is the most common mistake. I find that I can approach the trabecular meshwork best when my view is essentially parallel to the iris.

Properly filling the anterior chamber (AC) can enhance visualization. The AC should be completely filled to open the angle fully, but overfilling may compress the canal and should be avoided. Filling of the AC is complete when viscoelastic begins to exit the eye and the AC is fully inflated. In my experience, using a dispersive viscoelastic such as

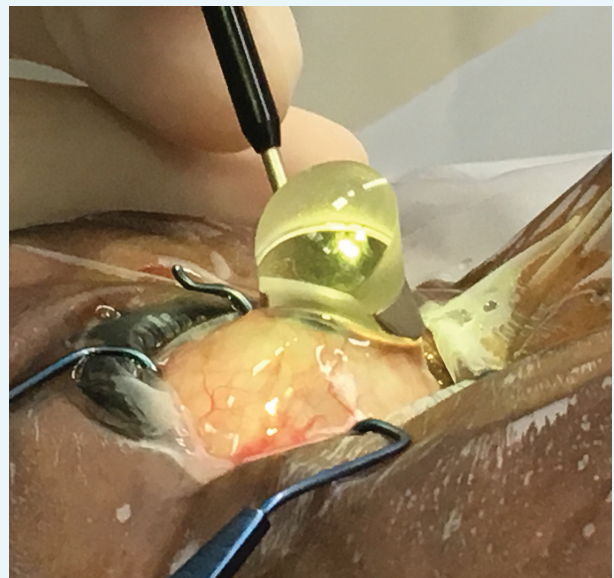


Figure. Gonioscope on the eye.

TABLE. RESULTS OF GONIOTOMY USING THE KAHOOK DUAL BLADE^a

Results for All Eyes							
	Preoperative	Day 1	Week 1	Month 1	Month 3	Month 6	Month 9
IOP, mm Hg	18.9 ±6.8	13.2 ±5.4	14.9 ±7.5	14.3 ±4.7	13.3 ±4.1	12.9 ±2.5	12.9 ±4.2
Mean difference, mm Hg	Reference	-5.7	-4.0	-4.6	-5.6	-5.8	-5.8
P value		< .001	< .001	< .001	< .001	< .001	< .001
Results for Combined Phacoemulsification and Goniotomy Using the Kahook Dual Blade							
	Preoperative	Day 1	Week 1	Month 1	Month 3	Month 6	Month 9
IOP, mm Hg	17.5 ±5.3	13.2 ±4.0	13.5 ±4.8	13.7 ±4.1	11.8 ±2.5	12.7 ±2.3	12.4 ±3.4
Mean difference, mm Hg	Reference	-5.5	-4.0	-3.8	-5.6	-4.7	-5.0
P value		< .001	< .001	< .001	< .001	< .001	< .001
Percentage of Eyes With a Reduction of at Least One Medication							
	Day 1	Week 1	Month 1	Month 3	Month 6	Month 9	
All surgeries	80%	73%	70%	83%	59%	73%	
Combined Phacoemulsification and Goniotomy Using the Kahook Dual Blade	74%	67%	66%	69%	63%	80%	

^aSummarized from Abdullah et al.³

Viscoat (Alcon) as well as a more cohesive viscoelastic such as Healon GV (Abbott) works well. I find that these agents maintain the AC nicely and do not easily reflux out during the procedure. Many surgeons also use carbachol intraocular solution (Miostat; Alcon), because they feel it helps create better exposure of the trabecular meshwork, which can be especially useful in eyes with lightly colored irises.

Visualization of the angle structures alone is not enough; proper positioning is essential. The surgeon's approach should be perpendicular to the trabecular meshwork. To achieve this, I position the patient's head so that the proximal edge of the gonioprism actually abuts or slightly covers the anterior portion of the clear corneal tunnel. If necessary, I gently lift the gonioprism when inserting the KDB. Slight contact between the anterior aspect of corneal tunnel and the edge of the gonioprism helps ensure proper head rotation. In this position, the angle structures are easily accessible, and the trabecular meshwork is more responsive to manipulation.

RESULTS

Researchers recently presented the results of a multi-center, prospective, cohort study in which 122 eyes underwent goniotomy with the KDB.³ Eight surgeons performed the procedure. The Table summarizes the results.

CASE EXAMPLES

A 68-year-old white woman with low-tension glaucoma underwent phacoemulsification combined with goniotomy

in both eyes. Her preoperative IOP on latanoprost alone was 12 mm Hg OU. Three months postoperatively, her IOP measured 9 mm Hg OU on latanoprost.

An 83-year-old white woman with moderate glaucoma underwent the combined procedure in both eyes. Her preoperative IOP measured 18 mm Hg OD and 19 mm Hg OS on four glaucoma medications. Three months postoperatively, her IOP measured 22 mm Hg OD and 18 mm Hg OS on no medication.

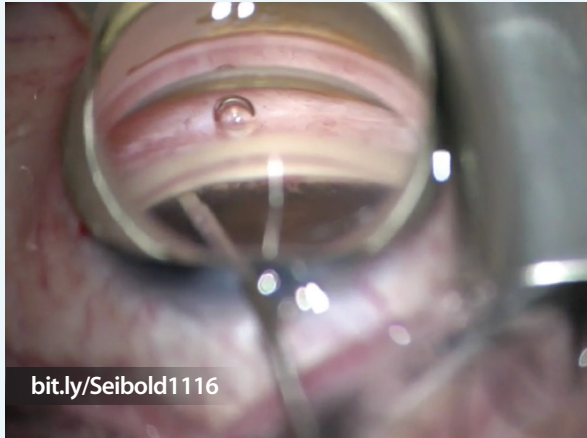


AT A GLANCE

- By removing a section of trabecular tissue, the Kahook Dual Blade gives aqueous direct access to the collector channels and the distal outflow system. Goniotomy with this device does not create a bleb or leave a foreign body inside the eye.
- An ophthalmologist who has not performed angle surgery will need to become comfortable using a gonioprism, a technique that requires practice. Proper positioning is also essential to success.
- Patients undergoing cataract surgery who also have controlled mild to moderate glaucoma are ideal for an ophthalmologist's first cases.

WATCH IT NOW

Leonard K. Seibold, MD, demonstrates goniotomy using the Kahook Dual Blade.



A 74-year-old white woman with mild open-angle glaucoma underwent the combined procedure on both eyes. Her preoperative IOP measured 15 mm Hg OD and 16 mm Hg OS on latanoprost. Three months postoperatively, her IOP measured 16 mm Hg OD and 17 mm Hg OS on no medication.

A 69-year-old African American woman with low-tension glaucoma underwent the combined procedure on both eyes. Her preoperative IOP measured 21 mm Hg OD and 22 mm Hg OS on one medication. Three months postoperatively, her IOP measured 19 mm Hg OD and 16 mm Hg OS on no medication.

CANDIDATES

Patients undergoing cataract surgery who also have controlled mild to moderate glaucoma are ideal first patients. The goal in this population is to reduce their dependence on glaucoma medication. After achieving success in this group, I began treating patients who needed better control of their disease and met with success in this population as well. Although I have performed the majority of goniotomy procedures on patients with mild to moderate glaucoma, I have also used the KDB on patients who have severe disease. I intend to continue to perform goniotomy on patients with all stages of glaucoma depending on the specific needs of the individual.

POSTOPERATIVE CARE

Postoperative care is straightforward. When the procedure is performed in conjunction with cataract surgery, I do not make any changes from routine postoperative care. Patients

undergoing goniotomy without cataract surgery require a short course of antibiotics and steroids. I find that mild steroids such as prednisolone phosphate 1% are sufficient. I do not routinely prescribe a nonsteroidal anti-inflammatory drug unless the patient is at risk of macular edema.

PITFALLS TO AVOID

Surgeons new to this procedure should be aware of a few potential complications, all of which are easy to avoid with proper attention to detail:

- When advancing the blade, it is important to carefully follow the canal. If the view becomes obscured, I advise stopping, reestablishing an acceptable view by injecting more viscoelastic, and then proceeding with treatment. If the KDB is advanced inferior to the canal, an iridodialysis could be created.
- If the surgeon chooses to turn the blade in the opposite direction inside the eye, he or she should be aware of the possibility of traumatizing the endothelium. This risk is mitigated by the very small profile of the tip.
- During removal of the trabecular tissue, blood reflux is common. If the amount of blood is excessive, I stop, remove the blade, and inject additional viscoelastic to tamponade the heme. This technique is effective in most cases. If necessary, irrigation and aspiration can be used to remove blood, followed by the injection of additional viscoelastic.

CONCLUSION

In my experience, goniotomy performed with the KDB is safe, effective, and easy to perform. Another advantage of the procedure is that it leaves no foreign body inside the eye. I have found postoperative care simple and straightforward, and I have been able to use the procedure for all stages of glaucoma. In my practice, patients who have the disease and are undergoing cataract surgery rarely decline its combination with goniotomy. I have achieved success both in terms of improving glaucoma control and reducing the medication burden on my patients, and I look forward to continued application of this exciting new procedure. ■

1. Wilensky JT, Gieser DK, Dietsche ML, et al. Individual variability in the diurnal intraocular pressure curve. *Ophthalmology*. 1993;100(6):940-944.
2. Asrani S, Zeimer R, Wilensky J, et al. Large diurnal fluctuations in intraocular pressure are an independent risk factor in patients with glaucoma. *J Glaucoma*. 2000;9(2):134-142.
3. Abdullah S, Jasek MC, Radcliffe NM, et al. A novel dual blade device for goniotomy: initial clinical experience. *Invest Ophthalmol Vis Sci*. 2016;57(12):6522.

Michael G. Morgan, MD

- chair, Department of Ophthalmology, Ochsner Clinic of Baton Rouge, Louisiana
- mcmorgan1617@gmail.com
- financial disclosure: has received honoraria from New World Medical